

# PRIMARY CARE OPTOMETRY NEWS®

A SLACK Incorporated® publication

The Leading Clinical Newspaper for Optometrists

PRIMARY CARE OPTOMETRY NEWS 6/1/2009

## Look to posterior capsule for complications after cataract surgery

Symposium participants detailed the signs of capsular distention and contraction and also discussed approaches to astigmatism correction.

*Jennifer LeCoq*

SAN FRANCISCO — Optometrists can easily diagnose postsurgical complications in cataract patients by carefully evaluating the posterior capsule.

Here at the spring session of the San Francisco Optometric Continuing Education Symposium, Victor Chin, MD, director of cataract and lens surgery at Pacific Vision Institute in San Francisco, described two syndromes – capsular distention and capsular contraction – that may arise after uncomplicated cataract or refractive lens exchange surgery and prevent the patient from achieving the optimal visual outcome.

### Capsular distention syndrome

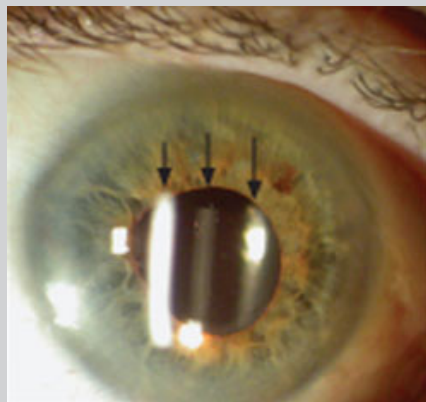
At the symposium sponsored by the Pacific Vision Institute and Pacific Vision Institute Research Foundation, Dr. Chin explained that in capsular distention syndrome, fluid or retained viscoelastic material is trapped between the IOL and the posterior capsule.

The accumulated fluid may be turbid and cloud the visual axis, causing glare and haze, he said. The distended capsular bag may also be filled with material with an index of refraction different from the aqueous, which thereby functions as an additional plus power lens in the optical system. This, coupled with any anterior displacement of the IOL from posterior pressure, may result in an unexpected myopic outcome.

Dr. Chin stated that in cases involving multifocal lenses, these symptoms may be magnified secondary to the diffractive optics of multifocal technology.

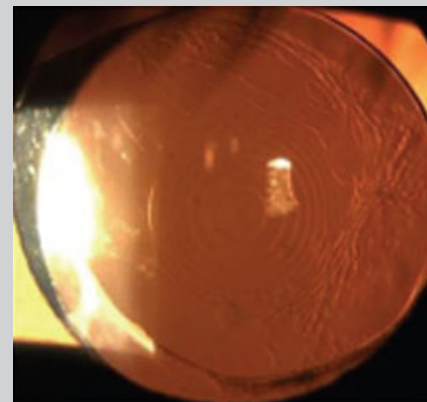
The leading theory that explains capsular distention syndrome suggests that the anterior surface of the IOL becomes occluded by a capsulorrhexis smaller in diameter than the optic of the new lens. The capsule adheres to the IOL, creating a potential space. Oncotic pressure from trapped substances such as viscoelastic can slowly draw fluid into this pocket, filling and distending the capsular bag.

Dr. Chin indicated that diagnosis can be easily made by looking at the space between the IOL and the posterior capsule. Normally, that space should be minimal and clear; in capsular distention syndrome, the space is obvious and often cloudy.



#### Capsular distention syndrome.

Capsular distention syndrome. The first arrow indicates the corneal light reflex, the second is the light reflecting off the IOL and the third light reflex represents the posterior capsule. Thick, cloudy fluid is in the intervening area between the IOL and posterior capsule



#### The ring of capsular wrinkling

The ring of capsular wrinkling in the midperiphery of the multifocal IOL may interfere with reading vision.

The treatment, Dr. Chin stated, is Nd:YAG laser capsulotomy to release the sequestered material. The procedure has a high success rate, reducing refractive error and improving the quality of vision.

### **Capsular contraction**

The quality of the posterior capsule should be evaluated especially carefully in patients with multifocal IOL implants, Dr. Chin added. Even small wrinkles can hinder good reading vision, for example, if they are located in the mid-periphery, over certain add zones. These patients may, in fact, have excellent distance vision, but poor reading vision.

Dr. Chin pointed out that before performing LASIK or PRK monovision to improve reading vision in patients who are not getting enough add with their multifocal IOL, the posterior capsule needs to be evaluated. A YAG laser capsulotomy should be performed before LASIK or PRK enhancement is performed.

Before performing a YAG laser capsulotomy, the entire posterior capsule should be examined. If the capsulotomy is performed only centrally, it may not result in improved near vision when capsular contraction and wrinkling is present peripherally even in accommodating IOLs. Peripheral capsulotomy is typically successful in improving near vision in these patients.

### **Correcting astigmatism**

For cataract surgery patients with astigmatism, an individual surgical plan must be established, reported Neil Friedman, MD, in another presentation. This private practitioner from Palo Alto, Calif., stated that the astigmatism can be corrected either intraoperatively or postoperatively.

During cataract surgery, options include limbal or corneal relaxing incisions (LRIs/CRIs), astigmatic keratotomy (AK) and the use of toric IOLs. After cataract surgery, astigmatism can be surgically corrected with laser vision correction or one of the aforementioned incisional techniques.

Establishing a surgical plan for each patient entails obtaining consistent measurements from multiple sources preoperatively, Dr. Friedman said. The refraction, keratometry and corneal topography measurements should be in agreement with respect to the magnitude and orientation of the astigmatism.

The effect of the cataract incision must also be considered. Once these numbers have been gathered, the desired correction is calculated using various nomograms or online calculators.

Dr. Friedman compared LRIs to the use of toric IOLs. LRIs are quick, easy to perform, low-tech and low-cost and can be enhanced at the slit-lamp postoperatively, he said. However, the outcomes are surgeon-dependent, with some degree of variability and unpredictability.

Toric IOLs have the advantage of being precise and predictable and require no new surgical skills; however, the technology is more costly. If the IOL rotates, it can result in a 3.3% loss of effect per 1 degree of rotation from the correct axis, Dr. Friedman said.

---

### **For more information:**

\* Pacific Vision Institute, One Daniel Burnham Court, San Francisco, CA 94109; (415) 922-9500; [www.pacificvision.org](http://www.pacificvision.org).